
Practice Guideline: **Disease Management**

**Provincial Consensus Recommendations on the
Evaluation, Diagnosis and Management of a
Suspicious Lateral Neck Mass**

Effective Date: November 2015

Preface

At CancerCare Manitoba (CCMB) the Clinical Practice Guidelines Initiative (CPGI) seeks to improve patient outcomes through the development, dissemination, implementation and evaluation of guidelines for the management of common clinical scenarios encountered by cancer patients throughout the province.

This clinical practice guideline was created through the efforts of a large interdisciplinary group from CCMB in collaboration with community partners. Members of the CCMB Head and Neck Disease Site Group (DSG), in collaboration with the Lymphoproliferative Disorders DSG, Department of Nursing, Department of Epidemiology, Department of Pathology, Department of Otolaryngology, Department of Radiology and the Department of Surgery at the University of Manitoba, general surgeons from the community, and oncologists from the Winnipeg Regional Health Authority (WRHA) Community Oncology Program and the Community Cancer Programs Network (CCPN) have participated in its development.

The Lymphoproliferative Disorders and Head and Neck DSG will review and update this document every five years, unless emerging evidence from scientific research, or practice issues requiring urgent resolution dictate a need for immediate change in content.

Purpose

This document is intended as a guide to facilitate a common approach to the evaluation and diagnosis of a suspicious lateral neck mass.

For this purpose, it may be used by qualified and licensed healthcare practitioners involved with the care of oncology patients, which may include (but is not limited to): physicians, surgeons, nurses, radiation therapists, pharmacists, psychosocial oncology caregivers and dieticians at CCMB, and Community Oncology Program sites (CCPN sites, Uniting Primary Care and Oncology Network (UPCON) clinics and WRHA Community Oncology Program sites).

Disclaimer

This guideline document should be viewed as an evidence-based practice tool, and as such, it does not represent an exhaustive text on the subject of head and neck cancer. Clinicians are advised to use it in their practice concomitantly with information from other evidence-based sources.

Use of this guideline in the clinical setting should not preclude use of the practitioner's independent clinical judgment, nor should it replace consultation with the appropriate oncology specialist when indicated (example: medical oncologist, radiation oncologist, family practitioner in oncology (FPO), nurse practitioner/clinical nurse specialist, pharmacist, psychosocial oncology professional and dietician).

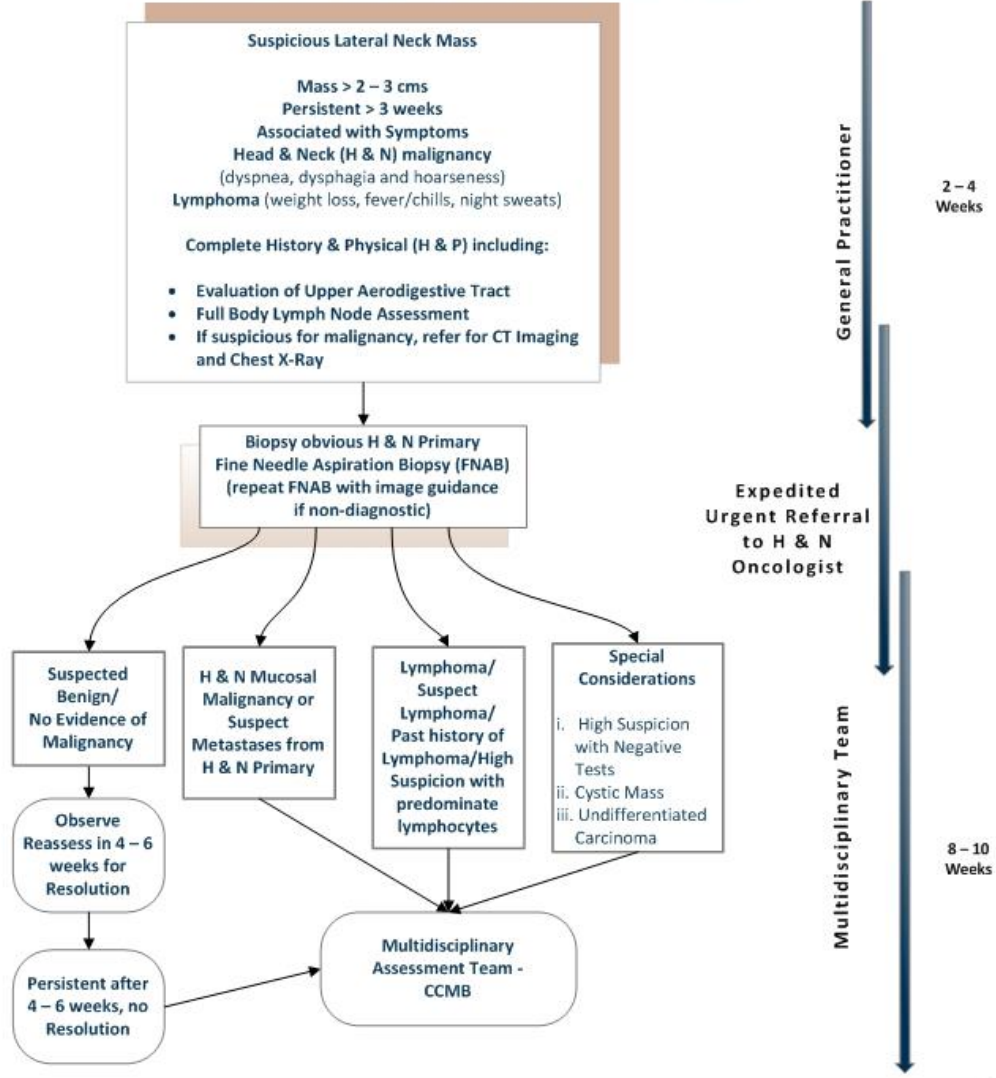
It is the responsibility of the practitioner to develop an individualized disease or symptom management plan for each patient under his/her care, and ideally, this should take place within the context of a multidisciplinary team. The needs and preferences of the patient and the family should always be reflected in the plan of care

Contents

Preface.....	2
Algorithm: Approach to the Lateral Neck Mass.....	4
Guideline Recommendations.....	5
I. Introduction: The Lateral Neck Mass in Manitoba.....	6
II. Scope of Guideline.....	7
III. Guideline Methodology.....	9
IV. Initial Assessment of a Lateral Neck Mass.....	13
V. Fine Needle Aspiration Biopsy and Imaging.....	16
VI. Diagnosis or Suspicion of Lymphoma.....	19
VII. Open Biopsy.....	22
VIII. Implementation and Dissemination.....	24
IX. Contact Physicians and Contributors.....	26
X. Conflicts of Interest.....	28
XI. Appendices.....	29
1. Neck Mass: Quality Indices	
2. Small Group Discussion	
3. Guiding Assumptions	
4. Levels of Evidence	
5. 2013 Head and Neck Provincial Consensus Meeting Agenda	
6. Abbreviations	
7. Definitions	

Algorithm: Approach to an Adult with a Lateral Neck Mass

APPROACH TO AN ADULT WITH A LATERAL NECK MASS



NOTES

Clinical Examination:

1. History – upper aerodigestive tract symptoms; constitutional symptoms; risk factors
2. Physical exam – cranial nerve exam; otoscopy; upper aero digestive tract; neck palpation including lymph node palpation above and below the clavicle
3. Fiberoptic Nasendoscopy
4. FNAB
5. When referring, include all relevant physical findings
6. Referral to occur if multiple lymph node groups are involved

Indications for Open biopsy*:

- i. Most cases of lymphoma
- ii. Further evaluation of undifferentiated malignancy
- iii. Cystic neck mass with no obvious primary
- iv. Non diagnostic FNAB (following 2nd biopsy under image guidance)
- v. Patient's condition indicates high suspicion for malignancy with negative investigations

* May be done in conjunction with EUA and panendoscopy in selected instances. Biopsy performed by or in consultation with member of multidisciplinary team

Special Considerations:

- i. Patients with known HIV, solid organ transplant, autoimmune disease, significant lymphadenopathy/splenomegaly, past history of lymphoma
- ii. Presence of lymphocytes is a red flag for Lymphoma

Guideline Recommendations

1. Malignancy is the major concern in an adult with a new lateral neck mass.
2. Initial assessment should include a complete history and physical with emphasis on the signs and symptoms of a head and neck primary cancer or lymphoma. A chest X-Ray is recommended. Thorough evaluation of the upper aerodigestive tract and all lymph node basins in the entire body are indicated.
3. Initial investigations include Fine Needle Aspiration Biopsy (FNAB) and imaging of the head and neck. If the FNAB comes back malignant, it is not necessary to wait for results of computed tomography (CT) scan imaging prior to referral. The imaging includes evaluation for a possible head and neck primary cancer. Contrast enhanced CT scan of the neck is appropriate and should be completed within 2 weeks. This should be arranged by contacting the radiologist.
4. A diagnosis or suspicion of malignancy should prompt expedited consultation with a Head and Neck oncologist for multidisciplinary assessment and treatment. If lymphoma is suspected, an early referral to a haematologist, in conjunction to surgical referral for a biopsy, is advised at the same time as initiating the appropriate work-up.
5. Open biopsy should only be performed by/or in communication with a member of the Head and Neck Disease Site Group (DSG).
6. The following data should be collected as measures of evaluation for the quality of guideline implementation:
 - a. date of presentation to primary care provider;
 - b. date of referral to CancerCare Manitoba;
 - c. date of first and subsequent FNAB;
 - d. number of FNAB's;
 - e. date of first diagnosis;
 - f. for lymphoma patients, date of definitive sub-typing diagnosis;
 - g. date of referral to CT scan;
 - h. date and site which imaging is performed;
 - i. date treatment plan initiated;
 - j. diagnosis of each FNAB.
7. Communication between practitioners is a key component to an expedient diagnosis.

CancerCare Manitoba

Disease Management Recommendations

Provincial Consensus Recommendations for the Evaluation, Diagnosis and Management of a Suspicious Lateral Neck Mass

I. Introduction

The solitary neck mass presents a number of diagnostic possibilities. There are numerous diagnostic procedures and approaches that can be applied in the management of patients, and these considerations can lead to an unintentional delay in diagnosis.¹ A systematic approach to the management of patients with a lateral neck mass was viewed as necessary.

Location of the mass in the neck and patient age help to narrow down potential causes.² The diagnosis of a midline neck mass is different from a lateral neck mass. Most neck masses at or near the midline, irrespective of age, are associated with the thyroid gland.¹ A lateral neck mass presents a more challenging problem. In children, inflammatory masses are the most common etiology followed by congenital lesions.⁴ In an adult presenting with a persistent lateral neck mass, clinical experience supports a diagnosis of a metastatic carcinoma or a lymphoma unless proven otherwise.¹⁻⁵

The evaluation and diagnosis of a lateral neck mass in the adult population emphasizes the expedient diagnosis of a malignancy with identification of a primary, if appropriate.

References

1. Balm AJM, van Velthuysen MLF, Hoebbers FJP, et al. Diagnosis and treatment of a neck node swelling suspicious for malignancy: an algorithmic approach. *Int J Surg Oncol* 2010;2010:1-9.
2. McQuirt WF. The neck mass. *Med Clin North Am* 1999;83(1):219-33.
3. Beenken SW, Maddox WA, Urist MM. Workup of a patient with a mass in the neck. *Adv Surg* 1995;28:371-83.
4. Lee J, Fernandes R. Neck masses: Evaluation and diagnostic approach. *Oral Maxillofac Surg Clin North Am* 2008;20(3):321-37.
5. Gleeson M, Herbert A, Richards A. Management of lateral neck masses in adults. *Brit Med J* 2000;320(7248):1521-24.

II. Scope of Guideline

Aim and Purpose

Development of this guideline was undertaken for the purpose of knowledge translation of the current standards in practice for treatment of head and neck cancer in Manitoba. The overall aim of the development is to improve the standard of care received by this patient population, through application of evidence-based interventions and promotion of best practices.

Clinical Question

From the current evidence in the literature, what algorithm, relevant to the setting of adult patients in Manitoba, can be developed for the evaluation, diagnosis and management of a suspicious* lateral neck mass?

*Defined as: > 6 weeks based on size criteria (> 1.5 cm), non-tender, no infectious cause, overlying skin changes, characteristic texture and mobility.

Development Panel

Development Panel

Oncology Subspecialties CancerCare Manitoba/University of Manitoba	<ul style="list-style-type: none"> 1 Medical Oncologist, Head and Neck DSG 2 Surgical Oncologist, Head and Neck DSG 1 Radiation Oncologist, Head and Neck DSG 1 Surgical Oncology resident 1 Pathologist 1 Cytopathologist 1 Physician, Community Oncology Program 1 Haematologist, Lymphoproliferative Disorders DSG
Radiology/Imaging Health Sciences Centre/University of Manitoba	1 Neuroradiologist
Quality, Patient Safety and Risk; Clinical Practice Guidelines Initiative CancerCare Manitoba	1 Quality/Guideline Development Professional

Development Process

A multidisciplinary group of medical professionals organized a conference to establish management consensus for adult patients with a suspicious lateral neck mass. Attendees were experts and practitioners from across the

province as well as an external expert (for impartiality). Presentations included evidence-based recommendations, as well as local expertise. The guidelines were developed using a modified Delphi consensus method (*See Section III - Guideline Methodology*).

Patient Population and Healthcare Setting

The recommendations in this guideline are applicable to the care of adult (18 years or older; male or female) patients with a suspicious lateral neck mass. These recommendations are intended for use in both inpatient and outpatient settings.

End-Users

This guideline is written for use by clinicians providing care for the above mentioned patient population. Intended primarily for use by medical clinicians, the guideline may be of interest to trainees, physician extenders, allied healthcare staff, healthcare administrators, policy-makers and possibly members of the general public.

III. Guideline Methodology

Clinical Research Question Development

Prior to beginning a literature search, the working group developed the clinical research question using the PICOT method (**P**opulation; **I**ntervention; **C**omparison; **O**utcome; **T**ime Frame). Discussion and consensus narrowed the clinical research question to:

From the current evidence in the literature, what algorithm, relevant to the setting of adult patients in Manitoba, can be developed for the evaluation, diagnosis and management of a suspicious lateral neck mass?*

**Defined as: > 6 weeks based on size criteria (> 1.5cm), non-tender, no infectious cause, overlying skin changes, characteristic texture and mobility.*

Literature Search

Clinical Practice Guidelines

PubMed, SAGE (Search Standards and Guidelines Evidence) Guideline Database, Google Scholar and Google (environmental search) were systematically searched for clinical practice guidelines. In SAGE, 109 results were found for head and neck cancer and 51 results with an applied limit for diagnostic assessment. The following search strategy was used to search for clinical practice guidelines in PubMed with humans as a limit, yielding 174 results. Some of the results were meta-analyses and reviews, not guidelines:

("Practice Guidelines as Topic"[Mesh] OR "Guideline" [Publication Type]) AND (Head and neck cancer [Mesh] OR (Head and Neck[Title/Abstract] AND (Neoplasm[Title/Abstract] OR Cancer*[Title/Abstract]))) AND ("Biopsy"[Mesh] OR "Biopsy, Fine-Needle"[Mesh]) AND (Biopsy [Title/Abstract] OR "Fine Needle" OR FNAB[Title/Abstract])*

Guidelines were also searched environmentally by guideline office including CancerCare Ontario, Alberta Health Services, BC Cancer Agency, Saskatchewan Cancer Agency, Government of Western Australia, National Comprehensive Cancer Network (NCCN), New Zealand Guidelines Group, Scottish Intercollegiate Guideline Network (SIGN) and National Institute for Health and Care Excellence (NICE).

Literature Review of Primary Evidence

Primary evidence was searched *via* PubMed, Google Scholar and Google. Literature was limited to the previous 15 years, human studies, English and an exclusion of thyroid cancers. The following search was conducted on head and neck diagnosis in PubMed and yielded 43 results:

(Cancer of the head and neck[MeSH] OR ((neoplasm[Title/Abstract] OR cancer*[Title/Abstract]) AND "head and neck"[Title/Abstract])) AND (("fine needle"[Title/Abstract] OR FNAB[Title/Abstract] OR excision*[Title/Abstract] OR incision*[Title/Abstract]) AND biopsy[MeSH]) AND ("neck lump"[Title/Abstract] OR "neck node"[Title/Abstract] OR "neck mass"[Title/Abstract] OR "Cervical lymphadenopathy"[Title/Abstract])*

A Google environmental search for publications was conducted using keywords “Head and Neck Cancer”, “diagnosis”, “neck mass”, “neck lump”, “neck node”, “Fine Needle Aspiration”, “biopsy”, “excisional” and “incisional”.

Reference Examination

The reference sections of particularly relevant guidelines and publications were examined for important publications that may have been missed.

After completing these 3 stages, 19 guidelines and 50 publications were found to be relevant to the clinical research question.

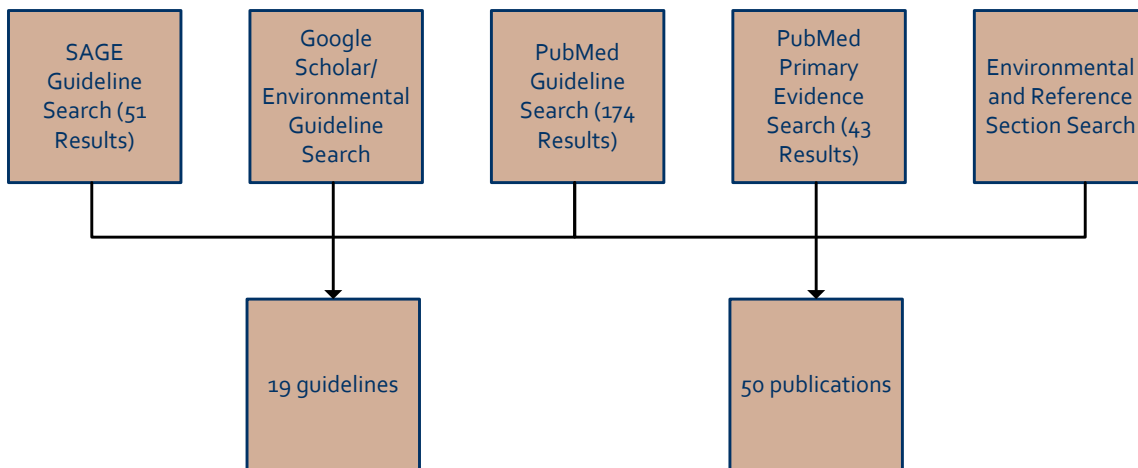


Figure 1. Literature Search Summary

2013 Head and Neck Provincial Consensus Meeting

A Provincial Consensus Meeting was held in Winnipeg, Manitoba on October 26, 2013. The working group met on six prior occasions to propose the current evidence and develop the agenda, budget, consensus statements and algorithm for this consensus meeting. The agenda included presentations of current evidence, a skills development sessions, a debate of current literature, small group discussions and a session devoted to the development of consensus statement recommendations. Logistical organization of the conference was completed by the Clinical Practice Guidelines Initiative.

The working group determined that the Modified Delphi Consensus Process would be used during discussion of the consensus statements at the conference. The Modified Delphi Consensus Process is defined as “...a method for structuring a group communication process so that the process is effective in allowing a group of individuals, as a whole, to deal with a complex problem.”¹ Guiding assumptions were adapted from those used at the CCMB 2011 Rectal Cancer Consensus Conference (See Appendix 3). During the conference, attendees were split into three small discussion groups to enable voting and encourage individual participation (See Appendix 2).

Consensus reached during small group discussion was then presented and discussed amongst the entire group. Consensus was reached with 75% agreement. Individually completed discussion booklets were collected and reviewed by the working group after the conference for additional consensus assessment.

The conference was attended by primary care providers, family physicians, nurse practitioners, surgeons (general and oncology), otolaryngologists, medical oncologists, radiation oncologists, radiologists, pathologists, residents, nurses and allied staff from CancerCare Manitoba and other urban and rural provincial health institutions. Attendees received accreditation through the Royal College of Physicians and Surgeons of Canada and the College of Family Physicians of Canada and the Manitoba Chapter.

2013 Head and Neck Provincial Consensus Meeting Attendees

Dr. A. Ahweng*	Dr. S. Ji	Dr. P. Moore	Dr. A. Sharma
Dr. B. Ali	L. Kendrick	J. Morissette	H. Sigvaldason
L. Alejandro-Yarema	Dr. P. Kerr	Dr. W. Myers*	Dr. J. Stone*
Dr. S. Battistuzzi	Dr. A.H. Khan*	Dr. C.R. Norman*	L.L. Turner
Dr. K. Brar	Dr. R. Kumar	P. McConnell	T. Toutant
M. Burfoot	V. Kytaychuk	S. McFall	N. Wiltshire
Dr. J. Butler	C. Laligo	Dr. P. Moore	Dr. D. Wong
J. Fisher-Cote	Dr. T. Le	J. Morissette	B. Wu
Dr. S. Ghazali	S. Magara	Dr. W. Myers*	Y. Xie
D. Grantman	P. McConnell	Dr. C.R. Norman*	
Dr. V. Hymaid*	S. McFall	K. Rebles	

*Indicates located in a rural setting.

Working Group Meetings

The working group developed this guideline in response to the consensus statements developed at the 2013 Head and Neck Provincial Consensus Meeting. The consensus statements formed the framework of the guideline and were integrated into the algorithm. Using the consensus statements for guidance, working group members drafted each of the guideline sections. Each section was reviewed by the working group and revised according to consensus decisions (*See Section IX for working group members*).

Internal and External Review

Internal and external peer reviews were pursued, the results of which are appended to these guidelines. The internal review process was consensus-based and completed by the working group. An external review was conducted by an otolaryngologist from McMaster University (Hamilton, Ontario), a pathologist from Toronto General Hospital (Ontario), and two family physicians in oncology from Gimli Community Health Centre and Boundary Trails Community Cancer Program in Manitoba respectively (*See Section IX*). All participants completed a full review of the guideline document and a standardized practitioner feedback survey (adapted from Brouwers and colleagues).² Feedback was considered and discussed by the working group. Decisions to incorporate any

changes into the guideline were consensus-based (acceptance, rejection or acceptance with modifications).

Maintenance

At CancerCare Manitoba clinical practice guidelines are considered 'living' documents which require ongoing evaluation, review and update. Re-evaluation of the guideline is planned for 2019. The Head and Neck Guideline working group will revise and update the document as needed, with any critical new evidence brought forward before this scheduled review.

References

1. Linstone HA, Turnoff M. The Delphi method: Techniques and applications. Reading, MA: Addison-Wesley Publishing Company;1975.
2. Brouwers MC, Graham ID, Hanna SE, et al. Clinicians' assessments of practice guidelines in oncology: the CAPGO survey. *Int J Technol Assess Health Care* 2004;20(4):421-6.

IV. Initial Assessment of a Lateral Neck Mass

Background

A number of benign and malignant diagnostic possibilities are associated with patients with a lateral neck mass. Malignancy is suspected if the neck mass is painless, palpably hard and enlarges over time. The two most common histologies are squamous cell carcinoma and lymphoma. A thorough history and physical examination can often help to determine which cancer may be present.

Key Evidence

A majority of publications examining the evaluation and diagnosis of an adult neck mass describe the authors' clinical experience and emphasize the importance of malignancy in their diagnostic approach.¹⁻⁵ Beenken and colleagues described "the rule of 80s" in an adult with a suspicious lateral neck mass - the cause is neoplasia in 80%, 80% of the neoplasms are malignant, 80% of the malignancies represent metastases, and 80% of these metastases are from above the clavicle.⁶ In a review of 699 adult patients presenting to a head and neck surgical oncology service at CancerCare Manitoba, 20% of patients were identified with a lateral neck mass and there was a documented final diagnosis (unpublished data); malignancy accounted for 40% of this cohort. The incidence of malignancy was significantly higher in patients older than 40 years old (45%) and in males (58%). Metastases to cervical lymph nodes and lymphoma accounted for 43% and 46% of the malignant diagnoses, respectively.

A careful history and physical examination can provide important clues to the diagnosis of a malignant neck mass.⁷ Excessive smoking, alcohol use and oral sexual practices are strongly associated with head and neck cancers.⁸ Common signs/symptoms include sore throat, difficulties with swallowing, ear pain, painful swallowing, or voice changes with hot potato speech or vocal hoarseness. For lymphomas, there is a strong association with HIV and immunodeficiency.⁹ In addition to lymphadenopathy, suspicion of lymphoma is raised in patients with fatigue, an abnormal complete blood cell count (CBC) with lymphocytosis or cytopenia, or "B" symptoms (unexplained weight loss, prolonged fever and drenching night sweats). Careful examination of the ear, nose, oral cavity, throat and assessment of lymph node regions in the head, neck, axilla, elbows, spleen, groin and behind the knee is essential.

Mediastinal lymphadenopathy or pulmonary metastases may be identified on a chest X-Ray; thus initial investigations should include a chest X-Ray in patients with a suspicious lateral neck mass.¹⁰ While computed tomography (CT) imaging provides more detailed anatomy, universal access and quick report time associated with chest X-Ray imaging is advantageous. The chest X-Ray findings may also help to establish the diagnosis of malignancy faster and expedite referral for further management.

Recommendations

Initial assessment should include a complete history and physical with emphasis on the signs and symptoms of a head and neck primary cancer or lymphoma. A chest X-Ray is recommended. Thorough evaluation of the upper aerodigestive tract and all lymph node basins in the entire body are indicated.

Clinical Considerations

- In patients with multiple node basin enlargement beyond the neck, and clinical symptoms suspicious of lymphoma, consider early excisional biopsy from other nodal basins including axillary or inguinal nodes to lower the risk for procedural complications compared to the head and neck region.
- Primary cancers from the head and neck region typically metastasize to specific cervical nodal regions; metastases higher in the cervical nodal regions (e.g., the submandibular region and near the angle of the jaw) are associated with a higher probability of a head and neck cancer.
- A low-lying neck mass can sometimes be associated with breast cancer as well as advanced lung cancer. A non-tender palpable mass in the left supraclavicular fossa is occasionally seen in patients with gastrointestinal malignancies, usually stomach cancer. This is known as Troisier's sign with enlargement of the left supraclavicular node (Virchow's node).
- Palpation of carcinoma tends to feel like a hard solid mass, whereas lymphoma has a firm, rubbery texture. Both are painless. If pain is elicited with palpation, the neck mass is less likely to be malignant.
- Physical exam should also include assessment of the spleen for splenomegaly in patients with extensive multi-site lymphadenopathy.
- Initiation of prompt referral within 2 weeks is recommended if any the following features of lymphadenopathy are present: persistence of ≥ 6 weeks; lymph nodes increasing in size over a few weeks; lymph nodes larger than 2 cm in diameter; widespread nature; associated splenomegaly, night sweats or weight loss.

References

1. Lee J, Fernandes R. Neck masses: evaluation and diagnostic approach. *Oral Maxillofac Surg Clin North Am* 2008;20(3):321-37.
2. Gleeson M, Herbert A, Richards A. Management of lateral neck masses in adults. *Brit Med J* 2000;320(7248):1521-4.
3. Balm AJM, van Velthuisen MLF, Hoebbers FJP, et al. Diagnosis and treatment of a neck node swelling suspicious for malignancy: an algorithmic approach. *Int J Surg Oncol* 2010;2010:1-9.
4. McQuirt WF. The neck mass. *Med Clin North Am* 1999;83(1):219-33.
5. Rosenberg TL, Brown JJ, Jefferson GD. Evaluating the adult patient with a neck mass. *Med Clin North Am* 2010;94(5):1017-29.
6. Beenken SW, Maddox WA, Urist MM. Workup of a patient with a mass in the neck. *Adv Surg* 1995;28:371-83.
7. National Institute for Health and Care Excellence. Referral guidelines for suspected cancer (NICE Clinical Guideline 27). National Institute of Clinical Excellence, London; 2005. Updated on 5 March 2014. Available online at: <http://www.nice.org.uk/CG027>. Accessed on 12 March 2014.

8. Argiris A, Karamouzis MV, Raben D, et al. Head and neck cancer. *Lancet* 2008;371(9625):1695-1709.
9. Skrabek P, Turner D, Seftel M. Epidemiology of non-Hodgkin lymphoma. *Transfus Apher Sci* 2013;49(2): 133-8.
10. Roland NJW, Woodcock B. Management of neck lumps guideline. National Health Services: Merseyside and Cheshire Cancer Network, United Kingdom; 2011. Updated March 2013. Available online at: <http://www.mccn.nhs.uk/>. Accessed on 12 March 2013.

V. Fine Needle Aspiration Biopsy and Imaging

Background

Diagnosis and staging of head and neck malignancy requires tissue confirmation, as well as an adequate assessment of anatomical extent of the tumour, regional lymph node metastasis and possible distant metastasis.¹ Fine needle aspiration biopsy (FNAB) for cytology is a safe, well-tolerated, effective first-line test of a lateral neck mass, with computed tomography (CT) imaging supplementation to evaluate extent of disease and identify a possible primary tumour.

Key Evidence

A meta-analysis and systematic review investigating the use of FNAB cytology in the diagnosis of head and neck cancers included 30 studies of Level II or III evidence. FNAB has an overall accuracy of 93% with a positive predictive value of 96% in diagnosing malignant and non-malignant head and neck masses.² A subsequent meta-analysis of 16 studies looking at the use of FNAB cytology of salivary gland lesions found that FNAB cytologic diagnosis of a malignant tumour and benign tumour was concordant in 80% and 96%, respectively.³ They concluded that FNAB was safe with reliable sensitivity and specificity.² Their final recommendation was that it remained a useful routine preoperative test. However, based on a negative predictive value of 90%, they stressed that a negative FNAB should not supersede clinical suspicion.² In summary, a negative FNAB result must be interpreted with caution, and in light of the clinical findings and other evidence.

T staging of the primary tumour requires accurate assessment of tumour size and relationship to critical deep structures.⁴ CT imaging is more sensitive than manual palpation and endoscopy at defining the T stage, and can in fact reveal a primary tumour in greater than 50% of lesions undetected on physical exam.⁴ As per the 2012 Canadian Association of Radiologists (CAR) Diagnostic Imaging Referral Guidelines, CT imaging is indicated for diagnosis in patients with clinically suspected occult or patients presenting with loco-regional or distant metastasis, to evaluate the full extent of the tumour.⁵ Further staging for prognosis and treatment plan relies heavily on evidence of regional and distant metastasis.⁴ According to the Ontario provincial guidelines for the management of head and neck cancer, the imaging study of choice of nodal metastasis is contrast enhanced CT to image from skull base to sternoclavicular joints.⁶ CT imaging remains the primary modality for the assessment of primary head and neck tumours and nodal metastases.⁷ This conclusion is reaffirmed by the American College of Radiology. The need for any further supplemental imaging scans can be reassessed as needed by the reviewing neuroradiologist.

Recommendations

Initial investigations include FNAB and imaging of the head and neck. If the FNAB comes back malignant, it is not necessary to wait for results of CT scan imaging prior to referral. The imaging includes evaluation for a possible head and neck primary cancer. Contrast enhanced CT scan of the neck is appropriate and should be completed within 2 weeks. This should be arranged by contacting the radiologist. The group felt that to expedite care, primary care and community based physicians who are appropriately trained and comfortable with the

procedure should perform a FNAB and arrange imaging of the primary tumour and entire neck based on clinical suspicion (see previous cautionary warnings regarding a negative FNAB result). After discussion, the group felt that the appropriate primary imaging study remained contrast-enhanced CT neck due to its availability and diagnostic accuracy. When further imaging studies, including magnetic resonance imaging (MRI) and positron emission tomography (PET) scan, are needed that can be arranged as per the head and neck radiologist, working in conjunction with the Head and Neck DSG. If the FNAB showed positive results suggestive of malignancy, including head and neck primaries and haematological cancers, then an urgent referral to the Head and Neck DSG should be made with documentation of the FNAB results to allow for appropriate triage of consults. In the setting of high clinical suspicion, irrespective of FNAB results, the group felt it would be appropriate for the referring physician to speak directly to a radiologist and physician at the Head and Neck DSG to expedite imaging studies and referral – as the proposed timeline for *urgent referral* and imaging studies is within 2 weeks.

Clinical Considerations

- FNAB can be arranged at the initial visit as it is a quick, easy and well-tolerated, minimally invasive investigation.
- As not to delay the appropriate referral and expedite care, primary care and community physicians can initiate these investigations while awaiting referral to the Head and Neck DSG.

References

1. Soben LH, Wittekind C (Eds.). *TNM Classification of Malignant Tumours*. Hoboken, NJ: Wiley; 2002.
2. Tandon S, Shahab R, Benton JI, et al. Fine-needle aspiration cytology in a regional head and neck cancer center: comparison with a systematic review and meta-analysis. *Head and Neck* 2008;30(9):1246-52.
3. Colella G, Cannavale R, Flamminio F, et al. Fine-needle aspiration cytology of salivary gland lesions: a systematic review. *J Oral Maxillofac Surg* 2010;68(9):2146-53.
4. Scottish Intercollegiate Guidelines Network. Diagnosis and management of head and neck cancer: a national clinical guideline. Updated 2006. Available online at: <http://www.sign.ac.uk/pdf/sign90.pdf>. Accessed 12 March 2014.
5. Canadian Association of Radiologists. Diagnostic imaging referral guidelines: head and neck. Updated 2012. Available online at: http://www.car.ca/uploads/standards%20guidelines/car-referralguidelines-b-en_20120918.pdf. Accessed 12 March 2014.
6. Gilbert R, Devries-Aboud M, Winquist E, et al.; Head and Neck Disease Site Group. The management of head and neck cancer in Ontario. Toronto(ON): Cancer Care Ontario; Program in Evidence-based Care Evidence-Based Series No.:5-3. Updated 2009. Available online at: <https://www.cancercare.on.ca>. Accessed on 12 March 2014.
7. BC Cancer Agency. Head and neck. Updated August 2006. Available online at: <http://www.bccancer.bc.ca>. Accessed on 12 March 2014.

8. Leslie A, Fyfe E, Guest P, et al. Staging of squamous cell carcinoma of the oral cavity and oropharynx: a comparison of MRI and CT in T- and N- staging. *J Comp Assist Tomo* 1999;23(1):43-9.

VI. Diagnosis or Suspicion of Lymphoma

Background

In building a guideline for approach to the suspicious lateral neck mass, epidemiology of the target patient population has been considered. Carcinomas and lymphoma can occur at any age; recognizing that carcinomas are more common in older patients, while lymphoma will be diagnosed in most young patients (ages 20-40) and represents up to half of malignant lateral neck masses.^{1,2} Increasingly we are seeing younger patients with oropharyngeal squamous cell carcinoma malignancies due to human papillomavirus (HPV). In the case of Hodgkin lymphoma, biopsy of a lateral neck mass is the most common means of diagnosis. The importance and potential impact of delay in diagnosis of lymphoma must be considered.

Key Evidence

This guideline recommends FNAB as initial step in patients with a lateral neck mass due to harm that has been associated with open biopsy in patients with carcinoma. While FNAB has good negative predictive value for carcinoma, its sensitivity for detection of lymphoma is variable. Series that report high sensitivity have few patients with diagnoses aside from B-cell non-Hodgkin lymphoma. False reassurance may be taken when FNAB is reported as reactive. Yet, this and other findings interpreted as benign have been reported in 20-41% of patients where open biopsy ultimately diagnosed lymphoma.^{3,4} Thus, the clinical context (*See "Special Considerations" on the algorithm*) must be applied. If disease is confined to the neck, FNAB is still the correct first step. However, if the disease is in the neck and multiple nodal basins, then targeting a non-neck region with excisional biopsy would be considered a reasonable first step.⁵ Appropriate use of initial diagnostic techniques including biopsies is critical to expedient diagnosis. Delays in diagnosis of lymphoma are greater than other common cancers.^{6,7} Diagnostic delays are even longer in young patients, and those ultimately diagnosed with Hodgkin lymphoma.⁸⁻¹⁰ Understandably, these considerations present management challenges and uncertainty for clinicians.

Most patients diagnosed with lymphoma, even those with advanced disease, are eligible for treatment with a high probability of remission.¹¹ Evidence is insufficient to determine whether shortened delays influence survival.¹² What is known is that length of diagnostic delay correlates with psychological distress.¹³ Furthermore, variables in clinical prognostic scoring systems for non-Hodgkin lymphoma and Hodgkin lymphoma are associated with higher disease burdens.¹¹ Patients with advanced stage lymphoma often require more chemotherapy and have an increased need for radiation.¹⁴

Recommendations

A diagnosis or suspicion of malignancy should prompt expedited consultation with a Head and Neck oncologist for multidisciplinary assessment and treatment. If lymphoma is suspected, an early referral to a haematologist, in conjunction to surgical referral for a biopsy, is advised. In evaluating a patient with a lateral neck mass, this algorithm suggests FNAB as initial step. If there is high suspicion of lymphoma based on patient history, imaging or other information (young age, B symptoms, multiple nodal basins, enlarged spleen), referral for definitive

biopsy and to the Lymphoproliferative Disorders DSG must proceed in a timely manner.

Clinical Considerations

- Lymphoma may be an overriding concern in persons between 20 and 40 years of age.
- A negative FNAB does not exclude lymphoma, and a referral for a definitive biopsy should be a strong consideration.
- A definitive biopsy requires experience in selecting the appropriate lymph node and an understanding of the complications in this region.

References

1. Yeo J, Lim SY, Hilmi OJ, et al. An analysis of non-head and neck primaries presenting to the neck lump clinic: our experience in two thousand nine hundred and six new patients. *Clin Otolaryngol* 2013;38(5):429-32.
2. Herd MK, Woods M, Anand R, et al. Lymphoma presenting in the neck: current concepts in diagnosis. *Brit J Oral Maxillofac Surg* 2012;50(4):309-13.
3. Morris-Stiff G, Cheang P, Key S, et al. Does the surgeon still have a role to play in the diagnosis and management of lymphomas? *World J Surg Oncol* 2008;6(13). Available online at: <http://www.wjso.com/content/6/1/13>. Accessed 12 March 2014.
4. Hay A, Pai I, Pitkin L, et al. Value of fine needle aspiration cytology in head and neck lymphoma: Experience in a head and neck cancer unit in the United Kingdom. *Acta Oto-laryngologica* 2011;131(11):1226-31.
5. Roland NJW & Woodcock B. Management of neck lumps guideline. National Health Services: Merseyside and Cheshire Cancer Network, United Kingdom. Updated March 2013 Available online at: <http://www.mccn.nhs.uk>. Assessed 12 March 2013.
6. Summerfield GP, Carey PJ, Galloway MJ, et al. An audit of delays in diagnosis and treatment of lymphoma in district hospitals in the northern region of the United Kingdom. *Clin Lab Haematol* 2000;22(3):157-60.
7. Allgar VL, Neal RD. Delays in the diagnosis of six cancers: analysis of data from the "National Survey of NHS Patients: Cancer". *Brit J Cancer* 2005;92(11):1959-70.
8. Howell DA, Smith AG, Roman E. Lymphoma: variations in time to diagnosis and treatment. *Eur J Cancer Care* 2006;15(3):272-8.
9. Neal RD, Allgar VL. Sociodemographic factors and delays in the diagnosis of six cancers: analysis of data from the "National Survey of NHS Patients: Cancer". *Brit J Cancer* 2005;92(11):1971-5.
10. Savage SA, Wotherspoon HA, Pentland D, et al. Cancer waiting times: what is the value of a lymphoma waiting time? *Scot Med J* 2008;53(3):5-7.
11. Narayanan S, Savage KJ. Staging and prognostic factors. In: Armitaage JO, Mauch PM, Harris HL, et al (Eds.). *Non-Hodgkin Lymphomas* (pp. 149-169). Philadelphia, PA: Lippincott Williams & Wilkins, a Wolters Kluwer business, 2009.

12. National Institute for Health and Care Excellence. Improving outcomes in haematological cancers: The research evidence. National Institute of Clinical Excellence, London. Updated 30 March 2010 Available online at: <http://www.nice.org.uk/guidance/>. Accessed 13 March 2014.
13. Risberg T, Sorbye SW, Norum J, et al. Diagnostic delay causes more psychological distress in female than in male cancer patients. *Anticancer Res* 1996;16(2):995-9.
14. Ansell SM. Hodgkin lymphoma: 2014 update on diagnosis, risk-stratification, and management. *Am J Hematol* 2014;89(7):771-9.

VII. Open Biopsy

Background

Definitive diagnosis of head and neck primary tumours requires a tissue confirmation via histopathology.¹ FNAB can be performed in the outpatient setting at the time of initial consultation, however it only allows for removal of cells without preserving the histological architecture of the lesion.¹ Open biopsies, including both incisional and excisional biopsies, allow for removal of tissue. An incisional biopsy removes only a sample of tissue, while an excisional biopsy removes the entire mass or suspicious area. Open biopsies are more invasive requiring either local or general anaesthetic – method decided upon based on tumour and patient factors, but requiring a planned, consented procedure that is done at a later date.¹

Key Evidence

Diagnosis and subtyping of lymphoma requires a tissue sample as cells obtained by FNAB are often insufficient. A clinical review investigating biopsy techniques in the diagnosis of lymphoma showed that only 29% of FNABs could classify with a specific lymphoma subtype.² In the setting of haematologic cancers the most common results of FNAB were abnormal findings (24%), non-diagnostic (21%) and lymphoma without subtype (19%).² Furthermore, 30% of T-cell lymphomas and 53% of Hodgkin lymphomas are classified on FNAB as benign or “non-diagnostic”.^{2,3} As previously mentioned, a *negative* FNAB result does not exclude lymphoma.⁴

However, a systematic review including 190 patients with cervical metastasis concluded that when open biopsies were performed on epithelial tumours there was a 2-3 fold incidence of local failure rates when compared to FNAB.⁵ Beyond increased risk of local failure, open biopsies have been shown to be detrimental to clinical management in the setting of squamous cell carcinoma as it complicates both subsequent surgical and radiation management, makes clinical examinations of the neck more difficult, encourages fungation and requires hospital admission and general anaesthetic.⁶

Recommendations

Open biopsy should only be performed by/or in communication with a member of the Head and Neck Disease Site Group (DSG). One of the goals of the working group was to review the evidence behind FNAB and an open biopsy as the initial investigation in the diagnosis of a lateral neck mass. FNAB is likely to be insufficient to diagnose a lymphoma as it does not allow for histological sub-typing or differentiate between reactive hyperplasia and low-grade non-Hodgkin lymphoma. Despite these challenges, FNAB remains a first-line investigation to safely rule out and avoid inappropriate incisional/excisional biopsy of epidermal-based tumours. It is a reasonable goal to provide an open biopsy and tissue sample with a FNAB suspicious for lymphoma within 2 weeks.

Clinical Considerations

- Before proceeding with an open biopsy, an exhaustive search for a head and neck primary must be

undertaken in order to avoid an unnecessary open procedure.

- In referral to the first consensus statement, in the initial assessment of a lateral neck mass, a complete history and physical should be performed by the referring physician – if there is palpable lymphadenopathy in a more accessible lymph node basin appropriate referral for expedited care should be made to the appropriate surgical team.
- Although FNAB is recommended for investigation of a lateral neck mass, it frequently does not result in a definitive lymphoma subtype and can be falsely negative in patients with lymphoma. However, given the risks associated with open biopsy of epidermal-based tumours, FNAB should be the initial biopsy. Open biopsy may still be required for lymphoma subtyping.

References

1. Herd MK, Woods M, Anand R, et al. Lymphoma presenting in the neck: current concepts in diagnosis. *Brit J Oral Maxillofac Surg* 2012;50(4):309-13.
2. Hehn ST, Grogan TM, Miller TP. Utility of fine-needle aspiration as a diagnostic technique in lymphoma. *J Clin Oncol* 2004;22(15):3046-52.
3. Roh JL, Lee YW, Kim JM. Clinical utility of fine-needle aspiration for diagnosis of head and neck lymphoma. *Eur J Surg Oncol* 2008;34(7):817-21.
4. Colella G, Cannavale R, Flamminio F, et al. Fine-needle aspiration cytology of salivary gland lesions: a systematic review. *J Oral Maxillofac Surg* 2010;68(9):2146-53
5. Gleeson M, Herbert A, Richards A. Management of lateral neck masses in adults. *Brit Med J* 2000;320(7248):1521-4.
6. Strojan P, Ferlito A, Langendijk JA, et al. Contemporary management of lymph node metastases from an unknown primary neck: II. A review of therapeutic options. *Head and Neck* 2013;35(2):286-93.

VIII. Implementation and Dissemination

The value of guidelines truly lies in their implementation and use. For that purpose, consideration was given to implementation during the planning of the consensus meeting, at the meeting, and during the drafting of this guideline document.

Local Consensus and Leader Support

As part of the knowledge translation approach, all physicians for whom these guidelines are applicable were invited to participate in the consensus meeting. There was an impressive response and good attendance. An outside expert was invited to speak and this was well appreciated by the attendees. A skills session was incorporated in the consensus meeting to encourage active participation and engagement of the attendees. Continuing Medical Education (CME) credits were provided.

Attendees from the meeting are expected to act as local opinion leaders disseminating and providing guidance to their colleagues on the recommendations developed at the consensus meeting.

CancerCare Resources

It was recognized during the meeting that resources would be needed to distribute these guidelines to the community. For that purpose, the guideline will be accessible online through the CancerCare Manitoba website. Online availability will be preceded by an e-blast notification with the website embedded. Announcement of the guideline and updates will be through established provincial communication channels; Community Oncology Program to CCPN rural sites, UPCON clinics and WRHA Community Oncology Program sites. This guideline will also be provided to partner organizations and guideline reviewers in other provinces. Use of the guideline in clinics will be through the online version.

Educational Events

Presentation of the guideline's recommendations will be made available at rounds and conferences; Head and Neck Case Conference rounds, CCMB Haematology/Oncology Regional Grand rounds, Allied Health rounds (Patient Services rounds), CCPN Community Cancer Care annual educational conference and at UPCON education and training events.

Evaluation

Evaluation of the guideline will be based on quality measures established by the working group and at the 2013 Head and Neck Consensus Meeting. These quality measures included:

- a. date of presentation to primary care provider;
- b. date of referral to CancerCare Manitoba;
- c. date of first and subsequent FNAB;

- d. number of FNAB's;
- e. date of first diagnosis;
- f. for lymphoma patients, date of definitive sub-typing diagnosis;
- g. date of referral to CT scan;
- h. date and site which imaging is performed;
- i. date treatment plan initiated;
- j. diagnosis of each FNAB.

NOTE: Please see Appendix 1 – Neck Mass: Quality Indices

IX. Contact Physicians and Contributors

Contact Physicians

Dr. Vallerie Gordon

Medical Oncologist, CancerCare Manitoba

Dr. Richard Nason

Surgical Oncologist, CancerCare Manitoba

Contributors

Consensus Meeting Organizing Committee	Presenters at the Consensus Meeting
Dr. Vallerie Gordon (Committee Chair and Meeting Moderator)	Dr. Diana Khalil
Dr. Diana Khalil	Dr. Jesus Medina
Dr. Shaun Loewen	Dr. Richard Nason
Dr. Richard Nason	Dr. Michel Nasr
Dr. Michel Nasr	Dr. Esther Ravinsky
Dr. Chris Ogaranko	Dr. Pamela Skrabek
Dr. Esther Ravinsky	Dr. Scott Sutherland
Dr. Pamela Skrabek	Dr. Norbert Viallet
Dr. Scott Sutherland	
Dr. Norbert Viallet	

External Reviewers

Dr. Stuart Archibald

Otolaryngologist, McMaster University

Dr. Bayardo Perez-Ordenez

Pathologist, Toronto General Hospital/Research Institute, University Health Network

Dr. Ramanbhai Chimanbhai Patel

Family Physician in Oncology, Gimli Community Health Centre

Dr. Cornelius Woelk

Family Physician in Oncology, Boundary Trails Community Cancer Program

Acknowledgements

We gratefully acknowledge the support of CancerCare Manitoba, the CancerCare Manitoba Foundation, the Provincial Oncology Clinical Practice Guidelines Initiative, and our external reviewers.

Approved By

Dr. Jim Butler, Radiation Oncologist
Chair, Head and Neck DSG

X. Conflicts of Interest

In accordance with the CancerCare Manitoba (CCMB) policy no. 01.001, “Conflict of Interest”, the authors of this guideline have disclosed conflicts of interest. Relationships with commercial interests were declared by two working group members; a Roche Unrestricted Educational Grant (Dr. Vallerie Gordon), attendance at a Roche Advisory Board meeting (Dr. Vallerie Gordon) and a Roche Honorarium (Dr. Pamela Skrabek). As members have adhered to the CCMB policy no. 01.014, “Interaction with Industry Representatives”, the developers are satisfied this guideline has been developed without bias and is based on best evidence and best practice. The authors of this guideline declare that no commercial support was received for their presentations at the 2013 Head and Neck Provincial Consensus Meeting or during development of this guideline.

XI. Appendices

Appendix 1

In the adult patient with a persistent lateral neck mass, the approach emphasizes the diagnosis of malignancy with identification of a primary site if appropriate. Algorithms for the diagnosis of a neck mass are based on clinical experience and expert opinion.¹⁻⁸ Quantitative data supporting these approaches is limited. Without this information it is difficult to standardize the diagnosis of a neck mass and there is risk of a self-sustaining cycle of misunderstanding. The Institute of Medicine defines quality as “the degree to which health services for individuals and populations increase the likelihood of desired health outcomes and are consistent with current professional knowledge”.⁹ A quality indicator is an agreed upon process or outcome measure that is used to assess quality of care. Implementing quality indicators that are reflective of the scope of care, feasible to implement and supported by evidence might help to identify areas and settings most in need of improvement.¹⁰

Neck Mass: Quality Indices

Index	Standard (common element) of Practice	References
Documentation of clinical assessment of upper aerodigestive tract prior presentation	Thorough evaluation of upper aerodigestive tract indicated in all patients with a suspicious neck mass	1-8,13,15
Documentation of clinical assessment of upper aerodigestive tract at initial assessment CCMB	Thorough evaluation of upper aerodigestive tract indicated in all patients with a suspicious neck mass	1-8,13,15
Documentation of clinical assessment of lymph node basins below clavicles at initial clinical assessment CCMB	Lymphoma and metastases from a primary below the clavicle are consistently considered in the differential diagnosis of a neck mass	1,4
FNAB performed	FNAB, with or without image guidance, is an accepted diagnostic tool in the first-line of assessment of a neck mass	1,2,4-7,21,22
FNAB repeated following initial non-diagnostic FNAB (under ultrasound guidance)	A negative or non-diagnostic study is an indication to repeat the FNAB	4,24,25,32
CT head and neck performed	CT is frequently used to characterize the neck mass and identify additional pathology including potential primary sites	2,13,19,33,34,36,38-43
Examination under anesthetic/panendoscopy with unknown primary	Examination under anesthetic with panendoscopy is supported by most investigators with metastases to the upper neck for a unknown primary suspected from a head and neck primary	1,4,5,13,34,39,42
Excisional biopsy of a neck mass without prior FNAB and/or head and neck imaging	Excisional or incisional biopsy is considered after: <ul style="list-style-type: none"> a single FNAB shows numerous lymphocytes and lymphoma is suspected two negative or non-diagnostic FNAB's and only after an aerodigestive tract primary has been carefully ruled out 	1,4,5,13,38

References

1. Beenken SW, Maddox WA, Urist MM. Workup of a patient with a mass in the neck. *Adv Surg* 1995;28:371-83.
2. Lee J, Fernandes R. Neck masses: Evaluation and diagnostic approach. *Oral Maxillofac Surg Clin North Am* 2008;20(3):321-37.
3. Gleeson M, Herbert A, Richards A. Management of lateral neck masses in adults. *Brit Med J* 2000;320(7248):1521-4.
4. Balm AJM, van Velthuisen MLF, Hoebbers FJP, et al. Diagnosis and treatment of a neck node swelling suspicious for malignancy: an algorithmic approach. *Int J Surg Oncol* 2010;2010:1-9.
5. McQuirt WF. The neck mass. *Med Clin North Am* 1999;83(1):219-33.
6. Rosenberg TL, Brown JJ, Jefferson GD. Evaluating the adult patient with a neck mass. *Med Clin North Am* 2010;94(5):1017-29.
7. Lefebvre JL, Coche-Dequeant B, Van JT, et al. Cervical lymph nodes from an unknown primary tumor in 190 patients. *Am J Surg* 1990;160(4):443-6.
8. Jones AS, Cook JA, Phillips DE, et al. Squamous carcinoma presenting as an enlarged cervical lymph node. *Cancer* 1993;72(5):1756-61.
9. Institute of Medicine. Announcement – “Crossing the quality chasm: the IOM health care quality initiative”. Available online at: <http://www.iom.edu/Global/News%20Announcements/Crossing-the-Quality-Chasm-The-IOM-Health-Care-Quality-Initiative.aspx>. Accessed 8 April 2014.
10. Seow H, Snyder CF, Mularski RA, et al. A framework for assessing quality indicators for cancer care at the end of life. *J Pain Symptom Manag* 2009;38(6):903-12.
11. Nason RW, Binahmed A, Abdoh A. Prognosis in oral cancer: beyond clinical staging. Presented at the meeting of: Prognosis in Head and Neck Cancer; Leiden, Netherlands, November 2005.
12. Hajjaj H, Pathak KA, Abdoh A, et al. Predicting long-term survival in squamous cell carcinoma of the tongue base: Assessment of evolving treatment strategies. Presented at the meeting of: International Academy of Oral Oncology: 34d World Congress; Singapore, July 2011.
13. Calabrese L, Jereczek-Fossa B, Jassem J, et al. Diagnosis and management of neck metastases from an unknown primary. *Acta Otorhinolaryngology* 2005;25(1):2-12.
14. Torsiglieri AJ Jr, Tom LW, Wetmore RF. Approach to the paediatric neck mass. *Transaction: Pennsylvania Acad Ophthalmol Otolaryngol* 1989;41:905-9
15. Schwetschenau E, Kelley D. The adult neck mass. *Am Family Physician* 2002;66(5):831-8.
16. Robbins KT, Shaha AR, Medina JE, et al. Consensus statement on the classification and terminology of neck dissection. *Arch Otolaryngol: Head and Neck Surgery* 2008;134(5):536-8.
17. Shah JP, Medina JE, Shaha AR, et al. Cervical lymph node metastasis. *Curr Prob Surg* 1993;30(3):1-335.

18. Lindbergh R. Distribution of cervical lymph node metastases from squamous cell carcinoma of the upper respiratory and digestive tract. *Cancer* 1972;29(6):1446-9.
19. Mendenhall WM, Mancuso AA, Parsons JT, et al. Diagnostic evaluation of squamous cell carcinoma metastatic to cervical lymph nodes from an unknown head and neck primary site. *Head and Neck* 1998; 20(8);739-44.
20. Balm AJ, Kroon BB, Hilgers FJ, et al. Lymph node metastases in the neck and parotid gland from an unknown primary melanoma. *Clin Otolaryngol Allied Sci* 1994;19(2):161-5.
21. Fathallah L, Tulunay OE, Feng J, et al. Histopathologic and cytopathologic diagnostic discrepancies in head and neck region: pitfalls, causes, and preventive strategies. *Otolaryngol: Head Neck Surg* 2006;134(2):302-8.
22. Tandon S, Shahab R, Bento J, et al. Fine needle aspiration biopsy in a regional head and neck cancer center: comparison with a systematic review and meta-analysis. *Head and Neck* 2008;30(9):146-52.
23. Smith EH. The hazards of fine-needle aspiration biopsy. *Ultrasound Med Biol* 1984;10(5):629-34.
24. Stanley MW. Selected problems in fine needle aspiration of head and neck masses. *Modern Pathol* 2002; 15(3):342-50.
25. Mighell AJ, High AS. Histological identification of carcinoma in 21 gauge needle tracks after fine needle aspiration biopsy of head and neck carcinoma. *J Clin Pathol* 1998;51(3)241-3.
26. Hehn ST, Grogan TM, Miller TP. Utility of fine-needle aspiration as a diagnostic technique in lymphoma. *J Clin Oncol* 2004;22(15):3046-52.
27. Ustün M, Risberg B, Davidson B, et al. Cystic change in metastatic lymph nodes: a common diagnostic pitfall in fine-needle aspiration cytology. *Diagn Cytopathol* 2002;27(6):387-92.
28. Cohen EG, Patel SG, Lin O, et al. Fine-needle aspiration biopsy of salivary gland lesions in a selected patient population. *Arch Otolaryngol: Head Neck Surg* 2004;130(6):773-8.
29. Jandu M, Webster K. The role of operator experience in fine needle aspiration cytology of head and neck masses. *Int J Oral Maxillofac Surg* 1999;28(6):441-4.
30. Cheng AT, Dorman B. Fine needle aspiration cytology: the Auckland experience. *ANZ J Surg* 1992;62(5): 368-72.
31. Begum S, Gillison ML, Nicol TL, et al. Detection of human papillomavirus-16 in fine-needle aspirates to determine tumor origin in patients with metastatic squamous cell carcinoma of the head and neck. *Clin Cancer Res* 2007;13(4):1186-91.
32. Shykhon M, Macnamara M, El-Assy A, et al. Role of repeat fine needle aspiration cytology in head and neck lesions: preliminary study. *J Laryngol Otol* 2004;118(4):294-8.
33. Nieder C, Gregoire V, Ang KK. Cervical lymph node metastases from occult squamous cell carcinoma: cut down a tree to get an apple? *Int J Rad Oncol Biol Physics* 2001;50(3):727-33.
34. Wartski M, Le Stanc E, Gontier E, et al. In search of an unknown primary tumour presenting with cervical

- metastases: performance of hybrid FDG-PET-CT. *Nuc Med Commun* 2007;28(5):365-71.
35. Wippold FJ II. Head and neck imaging: the role of CT and MRI. *Magnet Reson Imaging* 2007;5(3):453-65.
 36. van den Brekel MW. Lymph node metastases: CT and MRI. *Eur J Radiol* 2000;33(3):230-8
 37. Takeuchi Y, Numata T, Suzuki H, et al. Differential diagnosis of pulsatile neck masses by Doppler color flow imaging. *Ann Otol Rhinol Laryngol* 1995;104(8):633-8.
 38. National Institute of Health Guideline. Metastatic squamous neck cancer with occult primary treatment. Updated on 7 March 2014. Available online at: <http://www.cancer.gov/cancertopics/pdq/adulttreatment/>. Accessed 8 April 2014.
 39. Cianchetti M, Mancuso AA, Amdur RJ, et al. Diagnostic evaluation of squamous cell carcinoma metastatic to cervical lymph nodes from an unknown head and neck primary site. *Laryngoscope* 2009;119(12):2348-54.
 40. Fizazi K, Greco FA, Pavlidis N, et al. Cancers of unknown primary site: ESMO clinical practice guidelines for diagnosis, treatment, and follow-up. *Ann Oncol* 2007;22(6):64-8.
 41. Dong MJ, Zhao K, Liu ZF, et al. A meta-analysis of the value of fluorodeoxyglucose-PET/PET-CT in the evaluation of fever of unknown origin. *Eur J Radiol* 2011;80(3):834-44.
 42. Johansen J, Eigtved A, Buchwald C, et al. Implication of 18F-fluoro-2-deoxy-D-glucose positron emission tomography on management of carcinoma of unknown primary in the head and neck: a Danish cohort study. *Laryngoscope* 2002;112(11):2009-14.
 43. Stoeckli SJ, Mosna-Firlejczyk K, Goerres GW. Lymph node metastasis of squamous cell carcinoma from an unknown primary: impact of positron emission tomography. *Eur J Nuc Med Mol Imaging* 2003;30(3):411-6.

Appendix 2

Small Group Discussion*

Statement		Group A	Group B	Group C
1. Malignancy is the major concern in an adult with a lateral neck mass.	Support		8	10
	Do Not Support			
	Support with Modification	8		
	Modification	"Malignancy is the major concern in an adult with a lateral neck mass"		
2. Initial assessment should include a complete history and physical with emphasis on the signs and symptoms of a head and neck primary cancer or lymphoma. Thorough evaluation of the upper aerodigestive tract and lymph node basins are indicated.	Support			10
	Do Not Support			
	Support with Modification	8	8	
	Modification	"with addition of chest X-Ray"	"...all lymph node basins are indicated."	
3. Initial investigations include Fine Needle Aspiration Biopsy (FNAB) and imaging of the head and neck. The imaging includes evaluation for a possible head and neck primary cancer. Contrast enhanced CT scan and Chest X-Ray of the neck is appropriate. MRI may be appropriate in a supplemental role in select cases. Ultrasound is of limited value in this setting.	Support			
	Do Not Support			
	Support with Modification	8	8	10
	Modification	Change to contrast enhanced CT scan Delete last two sentences	Change to contrast enhanced CT scan Delete last two sentences Lymphoma needs to be included	Change to contrast enhanced CT scan Combine consensus statements 3 & 4 Add "Contrast CT should be completed within 2 weeks. If this has not been completed, contact Radiologist to achieve this."
4. A diagnosis or suspicion of malignancy should prompt expedited consultation with the Head and Neck oncology service for multidisciplinary assessment and treatment.	Support			
	Do Not Support			
	Support with Modification	8	8	10
	Modification	Add "If lymphoma is suspected an early referral to a haematologist is advised."	"change oncology service to oncologist"	"it is not clear who is to be contacted"

Statement		Group A	Group B	Group C
5. Excisional/incisional biopsy should only be performed by/or in consultation with a member of the Head and Neck Disease Site Group (DSG).	Support	8		
	Do Not Support			
	Support with Modification		8	10
	Modification		“Need to address synchronous referral”	“Excisional/ incisional biopsy of suspect metastatic carcinoma should only be performed...”
6. The following data should be collected as measures of evaluation for the quality of the guideline implementation: data of presentation to primary care provider; date of referral to multidisciplinary Head and Neck centre; date of first FNA; number of FNA’s; date of first diagnosis; for lymphoma patients, date of definitive sub-typing diagnosis.	Support	8		
	Do Not Support		8	
	Support with Modification			10
	Modification			Add: <ul style="list-style-type: none"> • Date of referral of CT scan • Date and site which imaging is performed • Date that treatment is initiated • Date of first FNA • Diagnosis of first FNA • Final diagnosis • Date treatment plan initiated
7. Additional Comments	Support	N/A	N/A	
	Do Not Support			
	Support with Modification			10
	Modification			Add a 7 th consensus statement: “ Communication between practitioners is a key component to expedient diagnosis. ”

*2013 CCMB Head and Neck Provincial Consensus Meeting

Appendix 3

Guiding Assumptions*

- Presenters' recommendations are based upon best available evidence
- Presenters are unbiased in their presentation of the best available literature
- Participants will use the data to assess the validity and appropriateness of the consensus statement
- Participants will remain unbiased and attempt to make decisions based on the best available evidence as presented
- All consensus items will be reviewed prior to discussion of any particular items where consensus has not been reached
- Consensus will be reached as a product of the discussion groups, first individually and then as a consortium
- Consensus is defined as 'agreement of 75% of participants in attendance at the afternoon session'
- If any participant leaves the conference before the end of the day, it will be assumed that he/she is in agreement with all of the final consensus statements
- Participants are expected to act as local opinion leaders and provide guidance to their clinical peers concerning the consensus information generated by this conference

* 2013 CCMB Head and Neck Provincial Consensus Meeting – Adapted from 2011 CCMB Rectal Cancer Consensus Conference

Appendix 4

Levels of Evidence

Ia	Evidence obtained from meta-analysis of randomised controlled trials
Ib	Evidence obtained from at least one randomised controlled trial
IIa	Evidence obtained from at least one well-designed controlled study without randomisation
IIb	Evidence obtained from at least one other type of well-designed, quasi- experimental study
III	Evidence obtained from well-designed, non-experimental descriptive studies, such as comparative studies, correlation studies and case studies
IV	Evidence obtained from expert committee reports or opinions and/or clinical experience of respected authorities

British Committee for Standards in Haematology 2007 <http://www.bcshguidelines.com>

Appendix 5

2013 Head and Neck Provincial Consensus Meeting Agenda

CONFERENCE AGENDA

8:00 – BREAKFAST		
8:30 – 8:45 Ambassador A Moderator: Dr. Vallerie Gordon Welcome, Introductions, and Opening Remarks		
8:45 – 9:30 Ambassador A Keynote Address	Dr. Jesus Medina "The Neck Mass – Standing up to the Diagnostic Challenge"	<ul style="list-style-type: none"> • Neck mass as a clinical problem • Appropriate initial assessment • Understand the technique and role of fine needle aspiration cytology • Appropriate use and interpretation of imaging • Importance of specialized multidisciplinary care with a suspect malignant neck mass
9:30 – 10:00 Presentation	Dr. Richard Nason/Heather Sigvaldason The Clinical Problem in Manitoba	<ul style="list-style-type: none"> • Identify the lateral neck mass in an adult in Manitoba as a sign of malignancy. • Describe the common pitfalls in the diagnosis of a neck mass that delay diagnosis and treatment.
10:00 – 10:15 – NUTRITION BREAK		
10:15 – 11:15 Ambassador A Considerations in Treating the Neck Mass	Dr. Esther Ravinsky "Fine Needle Aspiration Biopsy Neck Masses: Uses and Limitation"	<ul style="list-style-type: none"> • Have a better understanding of how to interpret the pathology report on a fine needle aspiration biopsy of a neck mass. • Understand the uses and limitations of fine needle aspiration biopsy of the neck.
	Dr. Michel Nasr "Making Sense of the Pathology Report – Challenges of FNA vs. Excisional Biopsy"	<ul style="list-style-type: none"> • Understand the hematolymphoid diagnostic challenges of FNA and small biopsies.
	Dr. Scott Sutherland "Imaging Approaches to the Lateral Neck Mass"	<ul style="list-style-type: none"> • Identify the different modalities available for neck imaging, contrasting strengths and weaknesses. • Recommend a suggested imaging approach to the patient presenting with a newly diagnosed mass in the lateral neck.
	Dr. Scott Sutherland "Differential Diagnosis in Imaging the Lateral Neck Mass"	<ul style="list-style-type: none"> • Review the appearance of common lateral neck masses. • Review the imaging criteria in the diagnosis of metastatic lymphadenopathy in the neck. • Identify atypical features in metastatic nodal disease in the neck, contrasted with benign cystic lesions in the neck.
11:15 – 12:00 Rotation to Skill Development Sessions	Dr. Norbert Viallet Bistro Lounge (main floor) Clinical Assessment of the Head and Neck	<ul style="list-style-type: none"> • Describe the normal clinical anatomy of the head and neck including the distribution of lymph nodes and anatomical divisions of the upper aerodigestive tract. • Perform a head and neck examination with an emphasis on identifying a possible primary malignancy in the upper aerodigestive tract.
	Dr. Shaun Loewen Altos Private Dining Room (2nd floor) Fiberoptic nasendoscopy	<ul style="list-style-type: none"> • Describe normal anatomy of the nasopharynx, oropharynx, hypopharynx and larynx as viewed through a fiberoptic nasendoscope. • Perform fiberoptic nasendoscopy
	Dr. Richard Nason Ambassador B (2nd floor) Fine Needle Aspiration Biopsy	<ul style="list-style-type: none"> • Describe the indications for fine needle aspiration biopsy in an adult patient presenting with a neck mass. • Perform a fine needle aspiration biopsy. • Prepare a Cytologic smear.
12:00 – 1:00 – LUNCH		
1:00 – 1:45 Ambassador A Literature Review and DEBATE on Findings	Dr. Diana Khalil Debate – "Safe and Efficient Diagnosis of a Lateral Neck Mass"	<ul style="list-style-type: none"> • A brief overview of the literature regarding the role of incisional vs excisional biopsies in safely and efficiently diagnosing the lateral neck mass.
	Dr. Pamela Skrabek Debate – "Safe and Efficient Diagnosis of a Lateral Neck Mass"	
	Dr. Vallerie Gordon – Moderator Question & Answer Session – "Safe and Efficient Diagnosis of a Lateral Neck Mass"	
1:45 – 2:00 Ambassador A Presentation	Dr. Norbert Viallet Proposed Standard of Care – "An Algorithm for Management of the Neck Mass"	
2:00 – 2:30 Small Group Discussion	Discussion – Algorithm and Consensus Recommendations Group 1 – Ambassador B (2nd floor) Group 2 – Altos Private Dining Room (2nd floor) Group 3 – Bistro Lounge (main floor)	Small Groups
2:30 – 2:45 – NUTRITION BREAK		
2:45 – 3:30 Ambassador A Reconvene	Consensus Recommendations	

Appendix 6

Abbreviations

CAR	Canadian Association of Radiologists
CBC	Complete blood cell count
CCMB	CancerCare Manitoba
CCPN	Community Cancer Programs Network
CME	Continuing Medical Education
CPGI	Clinical Practice Guidelines Initiative
CT	Computed Tomography (Imaging)
DSG	Disease Site Group
FNAB	Fine Needle Aspiration Biopsy
HIV	Human Immunodeficiency Virus
MRI	Magnetic Resonance Imaging
PET	Positron Emission Tomography
UPCON	Uniting Primary Care and Oncology Program (CCMB Community Oncology Program)
WRHA	Winnipeg Regional Health Authority

Appendix 7

Definitions

'B' symptoms	A group of symptoms associated with lymphomas including fever, night sweats and weight loss.
Chest X-Ray	An imaging procedure using ionizing radiation to create pictures of the inside of the chest, lungs, heart, large arteries, ribs and diaphragm.
Clinical Practice Guidelines	Systematically developed statements, informed by research evidence, values and local/regional context to assist provider and patient decisions about appropriate health care for specific clinical circumstances.
Computed Tomography (CT) imaging	An imaging procedure using X-Ray equipment to scan areas of the body in an aim to detect abnormal growths, help diagnose tumours, provide information about the extent or stage of disease, guide biopsy procedures and monitor for recurrence.
Cytopenia	Reduction in the production of one or more blood cell types. A deficiency in red blood cells is called anaemia; a deficiency in white blood cells is called leucopenia or neutropenia; a deficiency in platelets is thrombocytopenia; and a deficiency in granulocytes is granulocytopenia. Pancytopenia is a deficiency in red blood cells, white blood cells and platelets.
Disease Site Group (DSG)	Interdisciplinary working group with specific expertise of the disease-site. This group is responsible for clinical practice guideline development and aftercare.
Dysphagia	Difficulty swallowing
Dyspnea	Shortness of breath
Excisional biopsy	The surgical removal of the entire mass or abnormal area, with or without a margin of safety, so that it may be inspected under the microscope.
Fine Needle Aspiration Biopsy (FNAB)	A diagnostic procedure in which a sample of cells is drawn for cytological examination during the investigation of lumps or masses.
Haematologists	Medical specialists who study diseases of the blood and blood-forming organs.
Hodgkin lymphoma	A disease in which the lymph nodes become cancerous and lymphoma cells take on a particular microscopic appearance categorizing them as Reed-Sternberg cells.
Incisional biopsy	The surgical removal of a sample of a suspicious area, enough to make a diagnosis by viewing it under a microscope.
Lymphadenopathy	An abnormality to lymph node size, consistency or number.
Lymphocytes	A type of white blood cell that is made in the bone marrow and found in the blood and lymph tissue of the immune system.
Lymphocytosis	An increase in the number or proportion of lymphocytes in the blood.
Lymphoma	A general term referring to a group of related haematological cancers which develop in the lymphatic system.
Meta-Analysis	A quantitative statistical method used to contrast and combine results from different studies to increase the power of significant results and the precision of estimates.
Modified Delphi Consensus Method	A formal consensus method in which a panel of experts independently rate their agreement of subject recommendations (i.e., clinical practice guidelines). The recommendations are then collated and reviewed by the panel for consideration. This method improves transparency by following a systematic methodology.

Multidisciplinary team	A group consisting of members with specialized skills and expertise from different healthcare professions.
Negative predictive value	A statistical measure identifying a percentage of negative test results that are indeed true negatives.
Non-Hodgkin lymphoma	A heterogeneous group of lymphoproliferative cancers that start in the lymphocytes of the lymphatic system but have diverse patterns of behaviours and responses to treatments.
Open Biopsy	A procedure in which a surgical incision is made through the skin to expose and remove tissue for histopathological diagnosis.
Positive predictive value	A statistical measure identifying a percentage of positive test results that are indeed true positives.
Sensitivity	A statistical measure of the ability of a test to correctly classify positive results.
Specificity	A statistical measure of the ability of a test to correctly classify negative results.
Systematic Review	A literature review and critical assessment of the best available empirical evidence that meets pre-specified eligibility criteria to answer a given research question. Transparent procedures are used to identify, appraise, select and synthesize the results of this high quality research evidence.

CancerCare Manitoba
675 McDermot Avenue
Winnipeg, Manitoba, Canada
R3E 0V9
www.cancercare.mb.ca
CCMB Clinical Practice Guideline: Disease Management
Head and Neck Cancer
November 2015

CancerCare Manitoba,
November 2015. All rights reserved.

This material may be freely reproduced for educational and not-for-profit purposes.
No reproduction by or for commercial organization, or for commercial purposes is
allowed without written permission of CancerCare Manitoba.